

Female Pelvic Anatomy

Andreas Obermair

Queensland Centre for Gynaecological Cancer
 Professor, University of Queensland
www.obermair.info

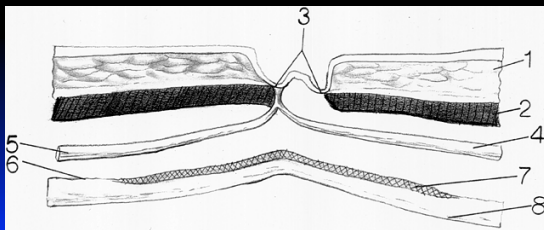
Layers of the abdominal wall



- Skin
- Fat
- Superficial fascia
- Muscle
- Sheath
- Preperitoneal fat
- Peritoneum

obermair.info

Umbilicus



- 1 subcut fat; 2 linea alba; 3 skin; 4 & 5 umbilical ligament & urachus; 6&7 transversalis fascia; 8 peritoneum

obermair.info

Umbilicus

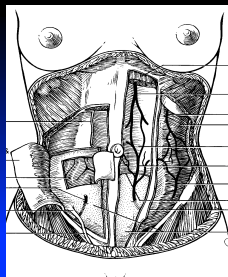
- Skin fused with linea alba, transversalis fascia, preperitoneal adipose tissue, and peritoneum;
- Devoid of fat and muscles.



obermair.info

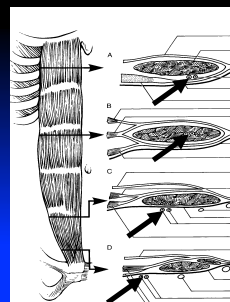
Inferior epigastric vessels

- **Arise**
 - External iliac vessels
- **Anastomose**
 - >> Superior epigastric vessels
 - >> Internal mammary vessels



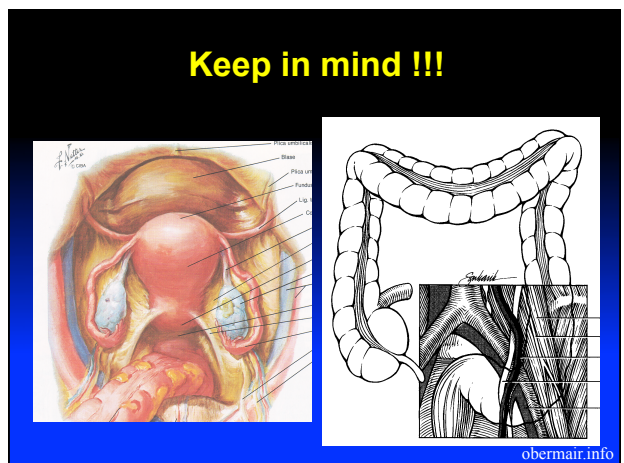
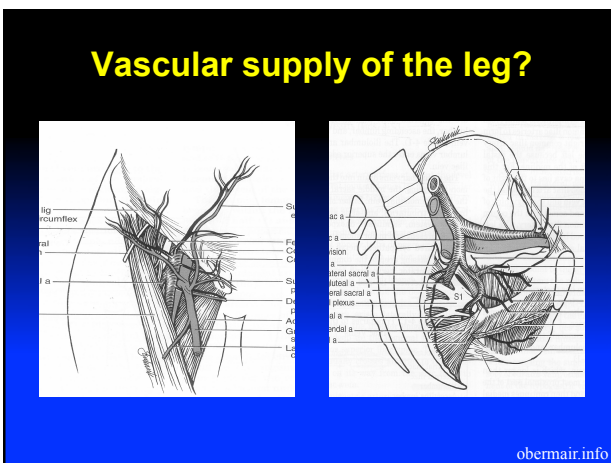
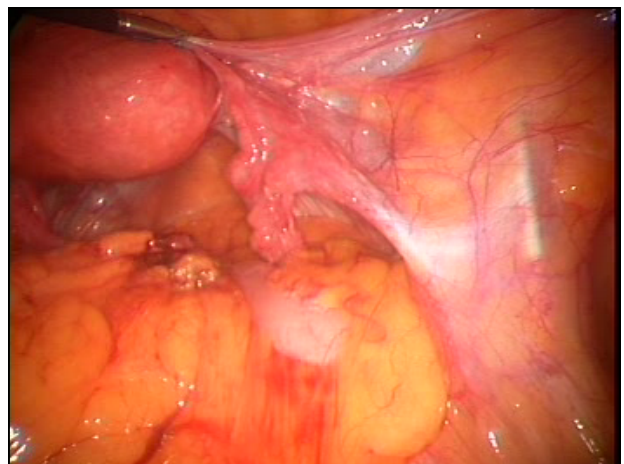
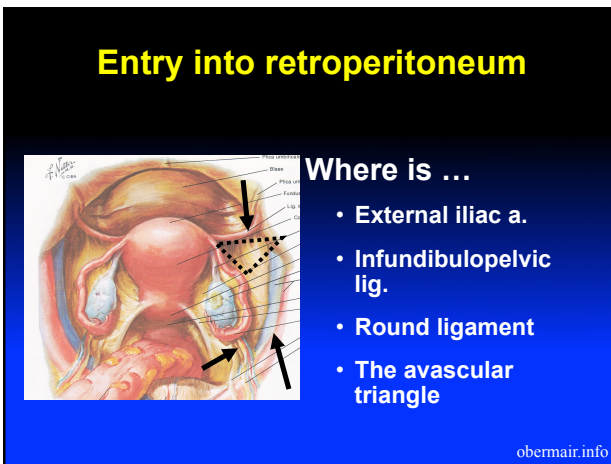
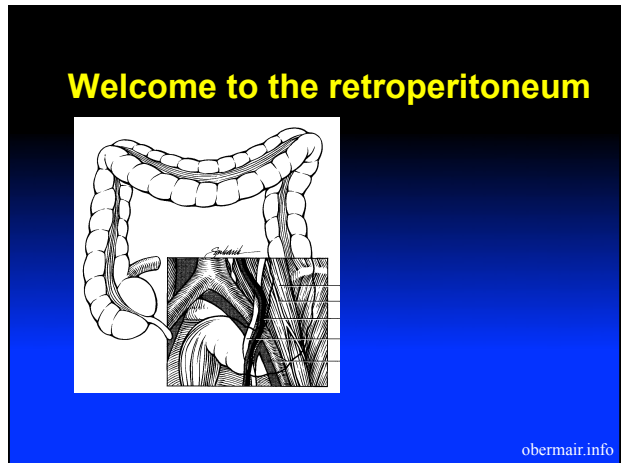
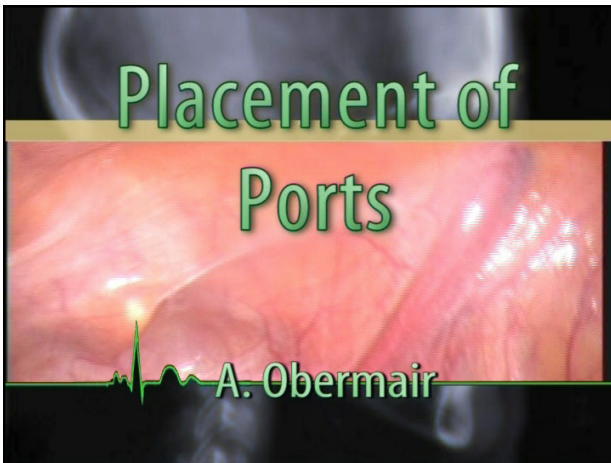
obermair.info

Inferior epigastric vessels



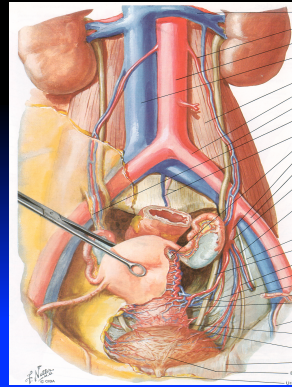
Key issues to secure the inferior epigastric vessels?

obermair.info



Blood supply pelvis

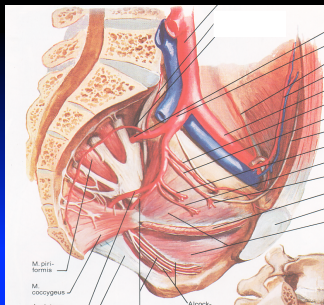
obermair.info



Arise of ovarian vessels?

obermair.info

Branches of internal iliac artery



Posterior trunk:

Parietal:

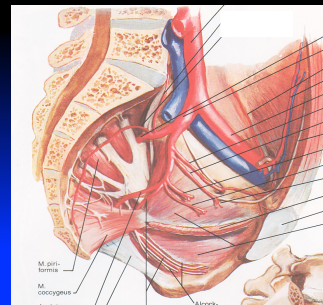
- Iliolumbar
- Lateral sacral
- Superior gluteal

Visceral:

- none

obermair.info

Branches of internal iliac artery



Anterior trunk

Parietal:

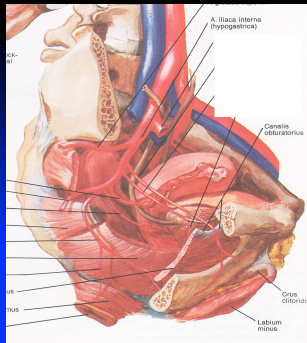
- Obturator
- Internal pudendal
- Inferior gluteal

Visceral:

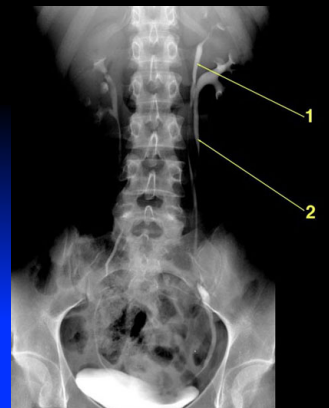
- Umbilical
- Uterine
- Vaginal
- Middle Rectal

obermair.info

Branches of internal iliac artery



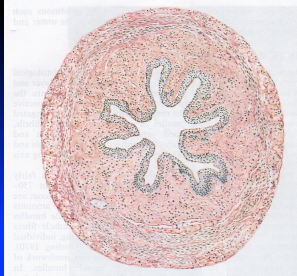
obermair.info



Anatomy of the pelvic ureter

obermair.info

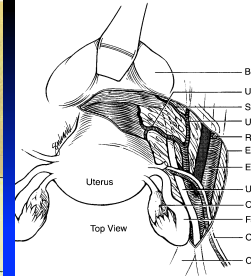

Anatomy of the pelvic ureter



Retroperitoneal
Attached to peritoneum
Fibromuscular & vermiculates (even if transected)

obermair.info

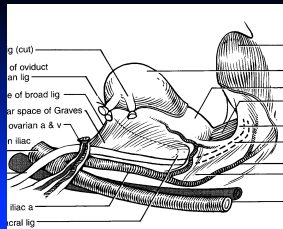
Anatomy of the pelvic ureter



obermair.info

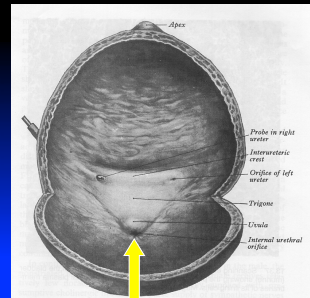
Blood supply of the "U"

- Not very forgiving !!!
- Vascular plexus



obermair.info

Who sutured a bladder ?



Closure:

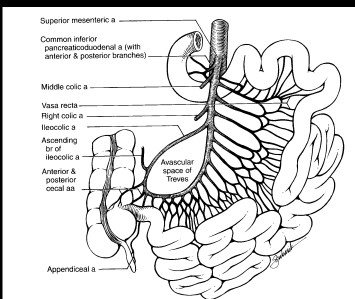
Two layers

Inner layer (epithelium and muscularis)

Outer seromuscular layer

obermair.info

Blood supply Small Bowel



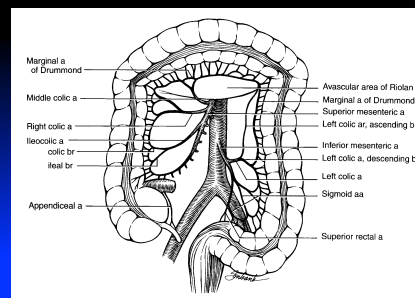
Superior Mesenteric A.:

- 4 branches to the Right
- Several Ileal and jejunal branches to the Left.

- Vasa recta (supplies approx 3-5 cm small bowel)
- No anastomoses between vasa recta
- Windows of Deaver

obermair.info

Blood supply Large Bowel



SMA:

Ileocolic a.
 Right colic a.
 Middle colic a.

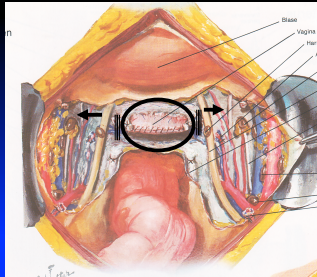
IMA:

Left colic a.
 Sigmoidal a.

Marginal artery of Drummond (incompleteness)

obermair.info

Bladder, ureter & uterine vessels




Here comes the tube

obermair.info

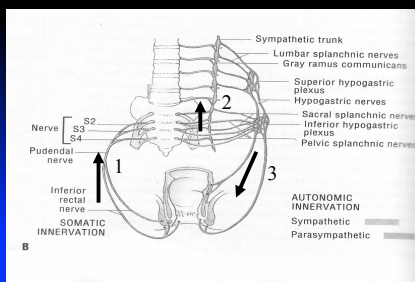
Micturition

- **Child** – reflexes only
 - Volume - Stretch receptors - pelvic splanchnic nerves – S 2,3,4, - parasympathetic (hypogastric) nerves to bladder muscle and pudendal nerve to sphincter.
- **Adult** – inhibition by higher centres in CNS



obermair.info

Pelvic Autonomous System



obermair.info

Parasympathetic outflow:

- S2,3,4;
- activates detrusor muscle,
- relaxes sphincter vesicae



obermair.info

Sympathetic Outflow

- L1,2;
- inhibit contraction of detrusor muscle;
- activate sphincter vesicae



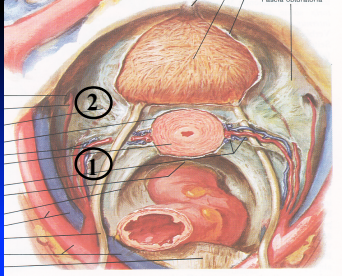
obermair.info

Nerve injury at lap surgery

- **Atonic bladder**
 - No bladder sensation
- **Shoulder tip pain**
- **Genitofemoral nerve** – sensory loss
- **Sciatic nerve** – sensory and motoric loss
- **Intercostal nerves** – sensory and motoric loss (pain, numbness)
- **Lumbar Plexus**
 - Weakness obturator/femoral nerve (adductors)
 - Sensory loss medial aspect of thigh (level)

obermair.info

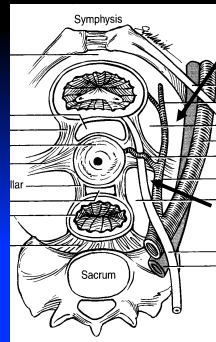
Pararectal & Paravesical Space



What structure lies between pararectal and paravesical space?

obermair.info

Pararectal & Paravesical Space



Paravesical

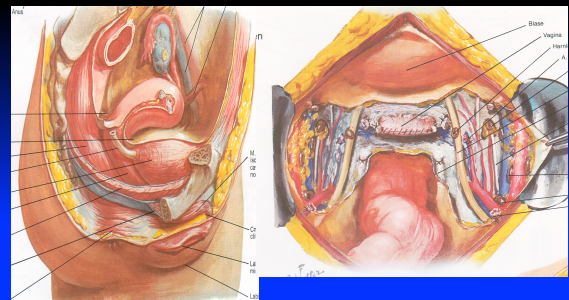
Pararectal

obermair.info

Pararectal & Paravesical space

A. Obermair

Peritoneum of Pouch of Douglas



obermair.info

More to read

- <http://obermair.info/research/online-presentations/>
- Obermair.info - [Blog](#)
 - Surgical training in gynaecology
 - New diagnostic + treatment methods
 - Surgical tricks (laparoscopic surgery on super obese women)

obermair.info